

# Reorganization of cerebral functional activity in persons with aphasia following language therapy.

Kuptsova S.V.<sup>1,2</sup>, Ivanova M.V.<sup>2</sup>, Akinina Y.S.<sup>2,3</sup>, Iskra E.V.<sup>1,2</sup>, Kozintseva E.G.<sup>1</sup>, Soloukhina O.A.<sup>2</sup>, Petrushevsky A.G.<sup>1</sup>, Fedina O.N.<sup>1</sup>

<sup>1</sup>Center for Speech Pathology and Neurorehabilitation (Russia), <sup>2</sup>National Research University Higher School of Economics (Russia), <sup>3</sup>University of Groningen (the Netherlands)

## Background

- The action naming task is reported to have greater diagnostic value in assessing word retrieval deficits than the traditionally used object naming task (e.g. Crepaldi et al., 2011; Rofes et al., 2014).
- Studies have demonstrated activation of the inferior frontal gyrus during action naming in healthy individuals with fMRI (Berlingeri et al., 2008), as well as deficits in verb retrieval in patients with lesions in this area (Rapp & Caramazza, 1997).
- Different studies of patients using Verb Network Strengthening Treatment (Edmonds, 2014) showed that following this therapy retrieval of trained and untrained but semantically related actions significantly improved (Edmonds&Babb, 2011; Edmonds, Mammino, Ojeda, 2014; Edmonds, Obermeyer, Kernan, 2014), however the neural substrate of such changes remains unexplored.

## Methods

### Participants.

Five patients with aphasia: two fluent and three non-fluent; mean age: 51.6; SD = 14.7; 3 men (All were right-handed native speakers of Russian). Two patients (P1, P2) with fluent aphasia had lesions in the posterior part of the left temporal lobe. One patient (P3) with non-fluent aphasia had a lesion in the posterior part of the left inferior frontal gyrus and the insula. Two patients (P4, P5) with non-fluent aphasia had lesions in the left posterior part of the frontal lobe, the anterior part of the temporal lobe and the inferior part of the parietal lobe.

**Therapy** (all verbal material was presented in Russian):

**1. Verb Network Strengthening Treatment** (VNeST; Edmonds, Nadeau, & Kiran, 2009; Edmonds, 2014), modified according to the specifics of the Russian language.

a) Generate agent-patient pairs.

who	bakes	what
girl	cake	
tourist	potatoes	
baker	bread	

If the patient can't generate pairs, four written words (three fillers and one target) are given to him, he has to choose the correct one.

b) Read aloud each agent-patient pair with the given verb.

c) Choose one agent-patient pair to discuss in more detail.

girl	bakes	cake
Where?	Why?	When?

d) Perform a sentence verification task with the target verb (16-20 sentences are presented with 75 % of them containing some kind of agent-patient violation)

e) Produce target verb independently.


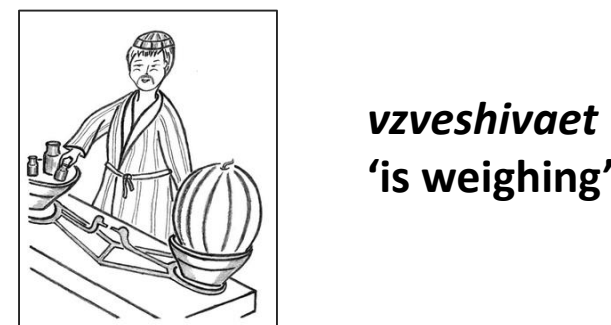
f) Repeat step a – generate agent-patient pairs again but without any cues from the clinician.

The patients received individual therapy 5 times a week for three weeks (40 min per session), three-four verbs in one session were treated according to this protocol.

### 2. Action naming task (fMRI study)

a) Experimental condition

What is the character doing in the picture? (72 verbs (30 – treated and 42 untrained which were presented only in fMRI study))



b) Control condition

Say a pseudoverb "kavaet".

## Aims of the study

Investigate behavioral and neural changes in action naming following intensive language therapy.

Explore the impact of lesion localization on these changes.

## Results

1. Behavioral results on the action naming task (presented as % correct)

№	Months post on set	Trained verbs (n=30)			Untrained verbs (n=30)			fMRI naming (n=72) change
		pre-therapy	post-therapy	change	pre-therapy	post-therapy	change	
P1	2	46.7	73.3	26.6*	33.3	51.7	18.4	18.1
P2	2	23.3	46.6	23.3*	23.3	16.7	-6.6	11.1
P3	6	63.3	76.7	13.33	60.0	70.0	10.0	13.9
P4	50	23.3	56.7	33.33*	26.7	33.3	6.6	20.8
P5	52	13.3	50.0	36.6**	16.7	33.3	16.6	22.2

McNemar test, \*p < .05, \*\* p < .01

2. fMRI data (all verbs > kavaet)

Healthy	P1	P2	P3	P4	P5
<b>pre-therapy</b>					
inferior frontal gyrus, inferior temporal gyrus of LH, occipital lobes bilaterally	inferior temporal-occipital area, precentral gyrus, parietal lobe LH; inferior temporal-occipital area RH	inferior temporal-occipital area LH; inferior temporal-occipital area RH	inferior temporal-occipital area, SMA, parietal lobe LH; SMA, inferior temporal-occipital area RH	frontal lobe LH; temporal-occipital area RH; frontal lobe RH; SMA bilateral	frontal lobe (mostly medial), parietal lobe, temporal and occipital area bilateral
<b>post-therapy</b>					
	temporal-occipital area, inferior frontal gyrus, SMA, parietal lobe LH; inferior temporal-occipital area RH	inferior frontal gyrus LH; inferior occipital area RH	inferior temporal-occipital area, inferior frontal gyrus, SMA, parietal lobe LH; inferior frontal gyrus, inferior temporal-occipital area RH	frontal lobe LH; temporal-occipital area RH; increasing activation in frontal lobe RH	inferior frontal gyrus, temporal and occipital area, TI RH; temporal-occipital area LH

## Discussion

➤ Effectiveness of the adapted VNeST protocol in Russian is demonstrated by establishing its specificity for the trained verbs and limited generalization to naming of untrained semantically unrelated verbs.

➤ Changes in patterns of activation following therapy are related to lesion localization: a) recovery of action naming seems to co-occur with perilesional reactivation and involvement of the inferior frontal region if this area is at least partly intact; b) RH activation was observed in patients with the extensive lesions in the frontal area.

➤ Intensive language therapy in patients leads to recruitment of brain areas which are activated in healthy participants during action naming or, in case of damage, activation of homologous areas in the RH.

• two fMRI sessions consisted of 18 blocks each 12 with real actions, 6 with abstract pictures, three pictures per block (presentation time 5.5 sec, ISI 0.5 sec)

• 1.5T Siemens Avanto scanner

BOLD: TE = 50 ms, TR = 3000 ms, FOV = 25 x 25 cm, 64 x 64 matrix, voxel dimension 3 x 3 x 3 mm high-resolution anatomical image: T1-weighted, MPRAGE; 0.98 x 0.98 x 1 mm; TE/TR 3/1900 ms

• fMRI data analysis was performed in SPM8

### 3. Behavioral testing

Pictures related to 30 trained verbs and 30 untrained semantically unrelated verbs were presented on the screen pre- and post-therapy to assess the therapy effects.